

PHOTOGRAMMETRIC MEASUREMENTS OF THE OPTIC DISC CUPPING AND  
RETINAL NERVE FIBER LAYER THICKNESS.

T. Takamoto, Ph.D., Associate Professor  
B. Schwartz, M.D., Ph.D., Professor and Chairman  
Department of Ophthalmology,  
New England Medical Center and  
Tufts University School of Medicine  
Boston, Massachusetts 02111, U.S.A  
ISPRS Commission V, 1988.

ABSTRACT

Most ophthalmologists use subjective methods to evaluate the optic disc for abnormalities and changes that occur in ocular hypertension and glaucoma. We have developed new techniques that allow more accurate evaluation of changes in disc cupping and pallor together with nerve fiber layer (NFL) thickness.

Cupping and NFL thickness of the optic disc are measured by photogrammetry from stereophotographs, which provide three-dimensional measurements not only of the volume of the cup, but of the depth, the slopes of the walls of the optic cup, and the area of the surface opening. The percent area of pallor of the optic disc is measured by computerized image analysis.

These techniques have been applied to clinical studies to evaluate optic disc hemorrhage, asymmetry of the optic disc cup, glaucoma-like discs, and reversibility of optic disc. These three techniques permit us not only to evaluate abnormalities, but to measure changes over time in the optic disc in ocular hypertension and glaucoma, thereby increasing our diagnostic capability and improving patient management.

INTRODUCTION

As early as 1857, after the introduction of the ophthalmoscope, cupping of the optic disc was considered an important sign in the diagnosis of glaucoma. At that time, von Graefe defined the disease as amaurosis with excavation of the optic nerve.<sup>1</sup> In 1922, Elliot<sup>2</sup> described pallor as a sign distinct from cupping. However, pallor and cupping were later confused with one another and "cupping" came to refer to both. More recent studies<sup>3,4</sup> have clearly distinguished cupping from pallor and have noted the importance of recognizing asymmetry of cupping<sup>5</sup> and pallor for early diagnosis of glaucoma. Disc changes generally occur before visual field changes.<sup>6</sup> Technologic advances in photogrammetry and image analysis have made possible more precise distinctions between cupping and pallor.

Two-dimensional techniques, such as direct ophthalmoscopy and evaluation of photographs, have been used to examine the nerve fiber layer (NFL) to assess in vivo glaucomatous changes of the optic nerve.<sup>7-14</sup> In recent years, an increasing number of reports have shown that retinal NFL examination is important in

the detection of very early glaucomatous changes.<sup>9,15-23</sup> These studies were based on qualitative evaluation of the NFL. Recently we developed a technique to evaluate NFL thickness quantitatively by photogrammetry.

We are using both image analysis for pallor and photogrammetry for cupping and NFL thickness to follow the development of visual field loss in ocular hypertensive (OH) and glaucomatous (OAG) eyes and to define adequacy of therapy. These techniques have been applied clinical studies and some of the results will be discussed in this paper.

## MEASUREMENTS OF THE OPTIC DISC

### Computerized image analysis of optic disc pallor

The system for measuring the optic disc pallor<sup>24</sup> consists of a VAX 11/780 mainframe computer (Digital Equipment Corp., Maynard, MA) with 2 megabytes of electronic memory and 700 megabytes of on-line magnetic disc storage. A Spatial Data Systems (Goleta, CA) EYECOM television camera with a chalnicon tube is used for image acquisition (512 x 512 pixels with 8 bits per pixel). The DeAnza Corporation's (Bervely Hills, CA) IP-5000 image display system are used (three channels of 512 x 512 pixels per channel for a total palette of 17 million colors).

Computer programs have been devised to trace the boundary of the optic disc and the boundary of pallor of the optic disc and to express the area of pallor as a percentage of the optic disc area.<sup>24,25</sup> Pallor measurement is reproducible on the order of 2% to 5% and requires about 5 seconds of computer time and 2 minutes of human time.<sup>24</sup>

### Photogrammetric measurement of optic disc cupping

We measured optic disc cupping by photogrammetry with a Kern stereoplotter (Kern Co., Ltd., Aarau, Switzerland) using stereophotographs taken with the Donaldson stereo fundus camera.<sup>26</sup>

The technique has been standardized to obtain high reproducibility by determining the effects of the variables of film type, magnification, exposure, and camera aperture. A simultaneous stereocamera is used to avoid the effects of eye movements that occur when stereophotographs are taken sequentially. Computer programs have been devised to determine the volume, depth, and area of the optic cup at the disc surface and the slope of the optic cup walls. These measurements are expressed relative to disc area. The reproducibility of the volume of the optic cup was 4 to 8%, expressed as a coefficient of variation (standard deviation/mean x 100).<sup>27</sup>

This technique also allows us to determine a volume profile of the cup: that is, its cross-sectional area from top to bottom. The volume profile characterizes the shape of the optic cup and shows distinct differences in shape between normal, ocular

hypertensive and glaucomatous cups.<sup>28</sup>

### Photography of retinal NFL

The visibility of the NFL varies considerably among individuals, even in those with normal eyes and clear media. This variation is related partly to the background pigmentation of the retinal pigment epithelium and choroid. In general, as the background becomes darker, the contrast and visibility of the NFL increases.

For two-dimensional NFL observation, Peli<sup>29</sup> et al found that photographs taken with a Canon CF-60Z were preferable to photographs taken with a Zeiss FF-111, and Panatomic-X film was superior to Plus-X film. The blue filter gave better contrast for the NFL in patients with lightly pigmented fundi, and the green filter resulted in less light scatter in patients with ocular media opacities.

Iwata<sup>19</sup> made qualitative stereo observations of NFL using 8X fundus color stereophotographs (6X6 cm) of eyes with early OAG, and reported its effectiveness for detecting slight thinning of NFL, which has fine-combed hair appearance in the Bjerrum area; and NFL defects which appear as dark slits or wedges.

### Retinal NFL thickness measurement by photogrammetry

We used 3X magnified, color, simultaneous stereophotographs, and 8X magnification provided by stereoplotter Kern PG2 (overall viewing magnification was  $3 \times 8 = 24$ ) to measure the NFL thickness. High magnification of color photographs may enhance stereo observation of NFL thickness as Iwata reported previously.<sup>19</sup>

NFL thickness was determined<sup>30</sup> by the depth between the surface of the internal limiting membrane and the retinal pigment epithelium along the disc margin measured at 5 degree intervals. To reduce the effect of photographic magnification, NFL thickness was expressed as a ratio to the vertical disc radius. The reproducibility of the photogrammetric method showed that the percent coefficients of variation were about 6%.<sup>30</sup>

In two-dimensional evaluation, slitlike or wedge-shaped defects can be detected by their apparent photographic contrast, but diffuse defects can not be evaluated this way. Experienced clinicians can recognize diffuse defects by their dark, flat texture, and the enhanced visibility of retinal vessels. Sommer,<sup>23</sup> however, reported considerable variation between two observers. Such variations caused by subjective evaluation should be minimized by our photogrammetric technique, which not only quantitates NFL thickness but also shows its distribution along the optic disc margin.

In our recent study,<sup>31</sup> significant differences ( $p < .001$ ) between normals, OH and OAG was found for frequency distributions of NFL thickness for total disc and for each quadrant. NFL thickness was decreased compared to normals by about 20% for OH and by

about 40% for OAG.

These observations correspond to those made of evaluation of the NFL from two-dimensional photographs of OH<sup>9,17,22,23</sup> and OAG.<sup>9,10,17,19,20</sup> The decrease of NFL thickness in OH supports other observations made of changes in OH eyes, such as an increase in area of fluorescein angiography defects.<sup>32</sup>

#### CLINICAL APPLICATIONS

##### Optic disc cupping and pallor measurements of patients with a disc hemorrhage<sup>33</sup>

In patients with glaucoma who have an optic disc hemorrhage, the incidence of visual field progression has been reported to be higher compared to control patients with similar visual fields<sup>34</sup> and fellow eyes without a disc hemorrhage.<sup>35</sup> Patients who are ocular hypertensive and have an optic disc hemorrhage have been shown to develop glaucomatous disc damage more often than patients without an optic disc hemorrhage.<sup>36</sup>

We compared 24 patients with a disc hemorrhage to 24 control patients, who had been matched for diagnosis, disc appearance, and visual fields.<sup>33</sup> Cup volume and cup-to-disc area ratio of the optic disc were measured using the stereophotogrammetric technique, and area of pallor was measured using computerized image analysis. We found that diabetes increased the probability that a patient would have a disc hemorrhage, and that a hemorrhage was associated with progression of glaucomatous disc changes in half of the cases during the 3 year follow-up period. However, the mean rate of glaucomatous disc damage in patients with a hemorrhage was not different from matched control patients. A disc hemorrhage is a sign of later disc damage, but it does not alter the rate of glaucomatous disc progression.

##### Asymmetry of the optic disc cup

Subjective evaluation of cupping of the optic discs of fellow eyes and their topographic differences has been an effective technique to detect early visual defects of glaucoma. Large cupping may exist in one eye while the other eye may maintain its original topography. Fishman<sup>37</sup> found an asymmetrical cupping in only 6% of normal individuals, but in 30% of patients with ocular hypertension without field defects and in 36% of those with glaucoma. While only 2% of normal infants were found to have an asymmetry of the discs,<sup>38</sup> asymmetry was found in 68% of glaucomatous infants.<sup>39</sup>

Stereophotogrammetric evaluations of the optic cup were performed for normal, ocular hypertensive, and glaucomatous eyes by Johnson et al.<sup>40</sup> Average volume, area, and depth measurements were progressively larger from normal to ocular hypertensive to glaucomatous eyes, although the distributions of individual values exhibited considerable overlap among the three groups. Similar results were obtained for volume, area, and depth

asymmetry between each pair of eyes. None of these measurements was able to distinguish accurately between normal and glaucomatous optic cups.

Using a photogrammetric technique we quantified asymmetry or differences of the volume profiles (the contour area of the optic cup from top to bottom is plotted along cup depth) between two eyes using 15 subjects; 5 normal, 5 ocular hypertensive, and 5 glaucomatous subjects and found significant differences ( $p < .01$ ) between these three groups.<sup>41</sup>

In our latest study<sup>42</sup> by photogrammetry we found a significant asymmetry ( $p < .03$ , left eye  $>$  right eye) in the normal group for the area and the volume of the cup (inferior quadrant), and for depth of the cup (superior quadrant). The OH group showed similar significant asymmetries ( $p < .001$ , left eye  $>$  right eye) for cup area and for cup volume (inferior quadrant) and cup depth (superior quadrant). However, the OH group was different from the normals in that the inferior quadrant depth is significantly different between the eyes ( $p < .0001$ ) with the right eye greater than the left. Mean visual field threshold values showed no significant differences between the eyes in both groups.

#### Glaucoma-like discs

We have reported<sup>43</sup> that glaucoma-like discs without increased intraocular pressure or visual field loss had similar shaped (measured by photogrammetry) cups when they were compared with those of the matched group of primary open angle glaucoma. In addition to increasing cup and pallor (measured by computer image analysis), they showed the higher prevalence of abnormal filling defect of the fluorescein in their optic discs and nerve fiber layer defect than that in the discs with normal appearances.

Recently, we found that in the follow-up of about 3 years there were statistically significant ( $p < .05$ ) increases in cup depth and cup volume of the group of glaucoma-like discs. In the normal group, significant ( $p < .05$ ) decreases were observed for cup volume. These results suggests that glaucoma-like discs were acquired changes and may represent an early stage of some type of open angle glaucoma.

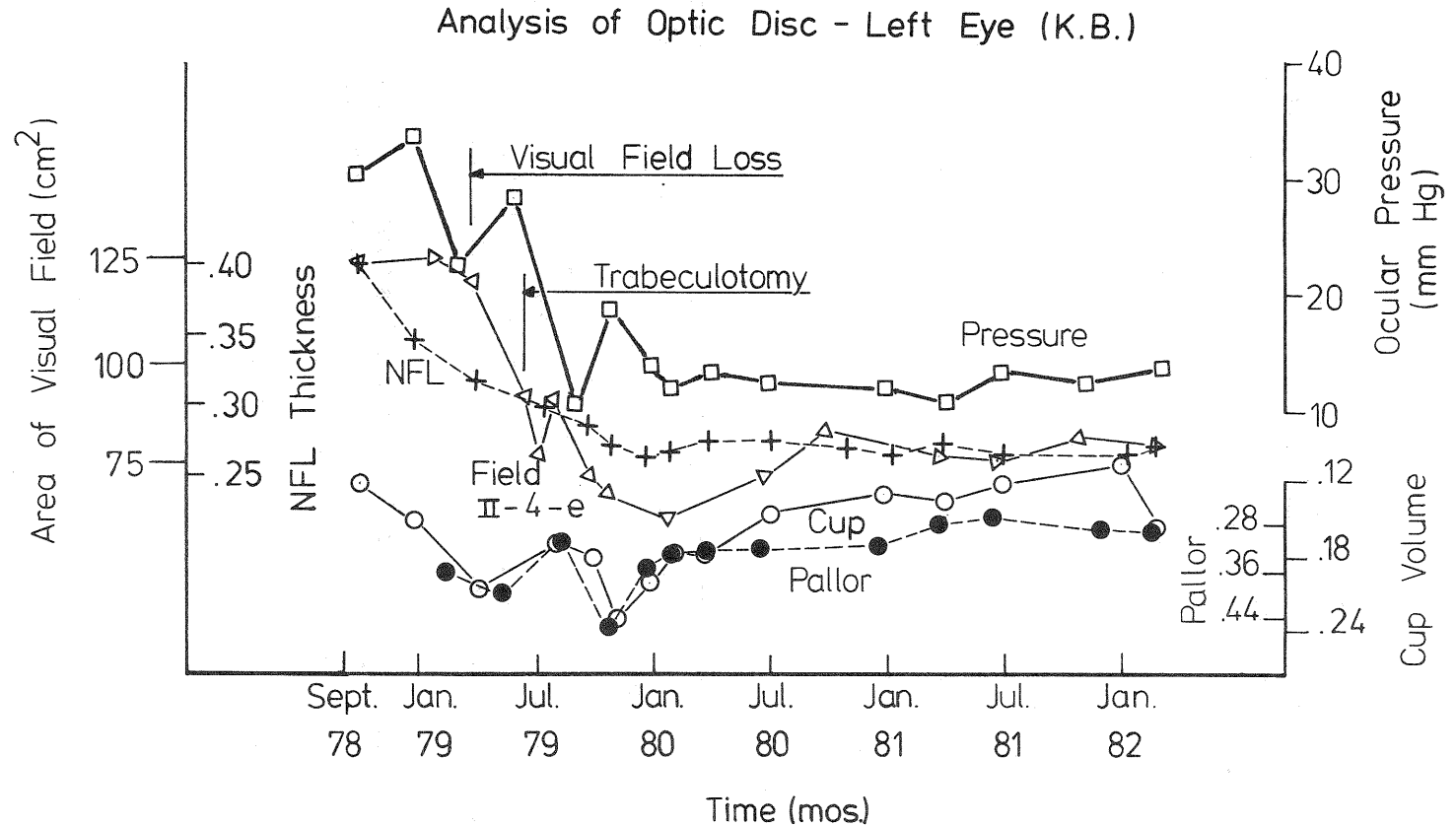


Figure 1. Reversibility of optic discs and visual field changes after surgery and subsequent medical therapy in a juvenile with secondary open-angle glaucoma. The course of the left eye was followed-up more than 3 years in relation to measurements of NFL thickness/disc radius, optic disc cup volume/disc area and pallor/disc area. Scale for cup volume and pallor was reversed so that upward trends show improved condition of the eye, as do visual field and NFL thickness.

## Reversibility of optic disc<sup>44</sup>

A young glaucoma patient who had both surgical and medical therapy showed reversal of cupping and pallor of the optic disc (Figure 1).<sup>44</sup> The optic disc and visual field changes corresponded to the changes in ocular pressures, generally showing worsening with an increase in ocular pressure. With a decrease in ocular pressure there was regression of visual field loss and a decrease in cupping (measured by photogrammetry); pallor (measured by computer image analysis) did not decrease consistently. The changes in cupping and pallor followed similar courses.

On the other hand, NFL thickness (measured by photogrammetry) along the optic disc margin showed rapid decreases before visual field loss and slow increases after surgery.<sup>30</sup> Since loss of NFL thickness was more rapid than reversibility of NFL thinning and preceded visual field loss, our photogrammetric technique may be effective in the detection of early visual field loss.

## Integration of cupping, pallor, and NFL thickness measurements

Disc changes precede visual field changes in the majority of patients.<sup>6</sup> Both prospective and retrospective studies of ocular hypertensive patients have shown the appearance of the disc to be an important factor related to future loss of visual field.<sup>45</sup> Recent attention has also been drawn to nerve fiber layer defects, especially those extending to the disc margin.<sup>46</sup> These defects are retinal changes, however, in glaucomatous eyes they seem to correlate with the appearance of the disc and with the presence of visual field loss. Their importance in predicting future visual field loss is unknown.

We have used photogrammetric techniques to study optic disc changes in ocular hypertensive and glaucomatous eyes, especially in relation to the development of field loss and the adequacy of therapy. As the next stage, we will integrate the measurements of cupping, pallor and NFL thickness by the computer into a single image, and the integrated image can be assessed in different orientations by the computer and the ophthalmologist to evaluate their interrelationship and their changes over time.

## ACKNOWLEDGMENTS

Supported in part by grant EY03661 from the National Eye Institute, National Institutes of Health, Bethesda, Maryland. The authors also wish to thank Benedicto L. Arevalo, B.S., for preparing this paper and Sarah Boardman, B.A., for editorial assistance.

## REFERENCES

1. Duke-Elder S, editor: System of ophthalmology. Vol. XI. Diseases of the Lens and Vitreous: Glaucoma and Hypotony. St Louis, The CV Mosby Co, 1969, p385.
2. Elliot RH: A Treatise on Glaucoma. London, Henry Frowde and Hodder and Stroughton Ltd, 1922, pp 195-218.
3. Chandler PA, Grant WM: Lectures on Glaucoma. Philadelphia, Lea and Febiger, 1965, pp 14-16.
4. Schwartz B: Cupping and pallor of the optic disc. Arch Ophthalmol 89:272-277, 1973.
5. Kirsch RB, Anderson DR: Clinical recognition of glaucomatous cupping. Am J Ophthalmol 75:442-454, 1973.
6. Pederson J, Anderson D: The mode of progressive disc cupping in ocular hypertension and glaucoma. Arch Ophthalmol 98:490-495, 1980.
7. Hoyt WF, Schlicke B, Eichelhoff RJ: Funduscopy appearance of a nerve-fiber-bundle defect. Br J Ophthalmol 56:577-583, 1972.
8. Hoyt WF, Frisen L, Newman NM: Fundoscopy of nerve fiber layer defects in glaucoma. Invest Ophthalmol 12:814-829, 1973.
9. Sommer A, Miller NR, Pollack I, Maumenee AE, George T: The nerve fiber layer in the diagnosis of glaucoma. Arch Ophthalmol 95:2149-2156, 1977.
10. Iwata K: Retinal nerve fiber layer, optic cupping and visual field changes in glaucoma. In: Glaucoma Contemporary International Concepts. Ed: Bellows JG, New York, Masson, Inc, pp 139-146, 1979.
11. Iwata K, Nanba K, Abe H: Die beginnende Fundus-veränderung infolge rezidivierender Kleiner Krisen beim Posner-Schlossman-Syndrom-eim Modell für das Glaucoma simplex: Klin Monatsbl Augenheilkd 180:20-26, 1982.
12. Quigley HA, Miller NR, George T: Clinical evaluation of nerve fiber layer atrophy as an indicator of glaucomatous optic nerve damage. Arch Ophthalmol 98:1564-1571, 1980.
13. Quigley HA, Sanchez RM, Dunkelberg GR, L'Hernault NL, Baginski TA: Chronic glaucoma selectively damages large optic nerve fibers. Invest Ophthalmol Vis Sci 28:913-920, 1987.
14. Quigley HA: Changes in the appearance of the optic disc. In "Early detection of glaucomatous damage." Surv Ophthalmol 30:111-126, 1985.
15. Sommer A, Pollack I, Maumenee AE: Optic disc parameters and onset of glaucomatous field loss. II. Static screening criteria. Arch Ophthalmol 97:1449-1454, 1979.
16. Airaksinen PJ, Mustonen E, Alanko HI: Optic disc haemorrhages precede retinal nerve fibre layer defects in ocular hypertension. Acta Ophthalmol (Kbh) 59:627-641, 1981.
17. Airaksinen PJ, Alanko HI: Effect of retinal nerve fiber loss on the optic disc nerve head configuration in early glaucoma. Albrecht Von Graefes Arch Klin Exp Ophthalmol 220:193-196, 1983.
18. Quigley HA, Addicks EM: Quantitative studies of retinal nerve fiber layer defects. Arch Ophthalmol 100:807-814, 1982.
19. Iwata K: The earliest finding of primary open-angle glaucoma and the mode of progression. In: Glaucoma Update II. Springer-Verlage, Berlin, pp 133-137, 1983.
20. Iwata K: Retinal nerve fiber layer abnormality in the earliest POAG. Analysis by contour synthesizer. Act Soc Oph-



- thalmol Jpn 87:507-518, 1983.
21. Airaksinen PJ, Nieminen H: Retinal nerve fiber layer photography in glaucoma. *Ophthalmology* 92:877-879, 1985.
  22. Airaksinen PJ, Drance SM, Douglas GR, Mawson DK, and Nieminen H: Diffuse and localized nerve fiber loss in glaucoma. *Am J Ophthalmol* 98:566-571, 1984.
  23. Sommer A, Quigley HA, Robin AL, Miller NR, Katz J, Arkell S: Evaluation of nerve fiber layer assessment. *Arch Ophthalmol* 102:1766-1771, 1984.
  24. Nagin P, Schwartz B, Nanba K. The reproducibility of computerized boundary analysis for measuring optic disc pallor in the normal optic disc. *Ophthalmol* 1985; 92:243-251.
  25. Nagin P, Schwartz B. Detection of increased pallor over time; computerized image analysis in untreated ocular hypertension. *Ophthalmol* 1985;92:252-260.
  26. Takamoto T, Schwartz B. Topographic parameters of the optic disc by the radial section method. *Proceedings of the American Society of Photogrammetry, Falls Church, Va., 1979;238-251.*
  27. Takamoto T, Schwartz B. Reproducibility of photogrammetric optic disc cup measurements. *Invest Ophthalmol Vis Sci* 26: 814-817, 1985.
  28. Takamoto T and Schwartz B: Quantification of cup shape in normals, ocular hypertensives and glaucomas. *Inv Ophthalmol Vis Sci (Suppl)*, 25:97-97, 1984.
  29. Peli E, Hedges TR III, McInnes T, Hamlin J, Schwartz B: Nerve fiber layer photography: A comparative study. *Acta Ophthalmol (Kbh)* 65:71-80, 1987.
  30. Takamoto T, Schwartz B, Mariner J: Follow-up study of retinal nerve fiber layer thickness measurements by photogrammetry, *proceedings of the American Society for Photogrammetry and Remote Sensing* 7:79-91, 1987.
  31. Takamoto T, Schwartz B: Photogrammetric nerve fiber layer (NFL) thickness measurements in normal, ocular hypertensive (OH), and glaucomatous (OAG) eyes. *Invest Ophthalmol Vis Sci (Suppl)* 29:421-421, 1988.
  32. Loebl M, Schwartz B: Fluorescein angiographic defects of the optic disc in ocular hypertension. *Arch Ophthalmol* 95:1980-1984, 1977.
  33. Tuulonen A, Takamoto T, Wu D, Schwartz B: Optic disc cupping and pallor measurements of patients with a disc hemorrhage, *Am J Ophthalmol* 103:505-511, 1987.
  34. Drance SM, Fairclough M, Butler DM, Kottler MS: The importance of disc hemorrhage in the prognosis of chronic open angle glaucoma. *Arch Ophthalmol* 95:226-228, 1977.
  35. Shihab ZM, Lee PF, Hay P: The significance of disc hemorrhage in open-angle glaucoma. *Ophthalmology* 89:211-213, 1982.
  36. Airaksinen PJ, Tuulonen A: Early glaucomatous changes with and without an optic disc haemorrhage. *Acta Ophthalmol* 62: 197-202, 1984.
  37. Fishman RS: Optic disc asymmetry. A sign of ocular hypertension. *Arch Ophthalmol* 84:590-594, 1970.
  38. Shaffer RN and Weiss DI: *Congenital and paediatric glaucomas.* St. Louis, C.V. Mosby, 1970.
  39. Shaffer RN and Hetherington J: The glaucomatous disc in infants. A suggested hypothesis for disc cupping. *Tr Am Acad Ophth and Otol* 73:929-935, 1969.

40. Johnson CA, Keltner JL, Krohn MA, and Portney GL: Photogrammetry of the optic disc in glaucoma and ocular hypertension with simultaneous stereo photography. Invest Ophthalmol Vis Sci 18:1252-1262, 1979.
41. Takamoto T, Schwartz B: Quantification of asymmetry of the optic disc cup by photogrammetry, proceedings of the American Society for Photogrammetry and Remote Sensing 3:7-16, 1988.
42. Carassa R, Schwartz B, Takamoto T: Measurement of optic disc asymmetry in normals and ocular hypertensives. Invest Ophthalmol Vis Sci (Suppl) 29:355-355, 1988.
43. Tomita G, Takamoto T, Schwartz B: Glaucoma-like discs without increased ocular pressure or visual field loss. Invest Ophthalmol Vis Sci (Suppl) 28:61-61, 1987.
44. Schwartz B, Takamoto T, Nagin P: Measurements of reversibility of optic disc cupping and pallor in ocular hypertension and glaucoma. Ophthalmol 92:1396-1407, 1985.
45. Kass MA, Hart WM, Gordon M, Miller P: Risk factors favoring the development of glaucomatous visual field loss in ocular hypertension. Surv Ophthalmol 25:155-162, 1980.
46. Quigley HA, Miller NR, George T: Clinical evaluation of nerve fiber layer atrophy as an indicator of glaucomatous optic nerve damage. Arch Ophthalmol 98:1564-1571, 1980.