

ANALYSING THE FACIAL MORPHOLOGY WITH A THREE-DIMENSIONAL GEOMETRICAL FEATURES APPROACH

F. Calignano^a, S. Moos^a, E. Vezzetti^{a*}

^a Politecnico di Torino, Dipartimento di Sistemi di Produzione ed Economia dell’Azienda, 10129 Torino, Italy - (flaviana.calignano, sandro.moos, enrico.vezzetti)@polito.it

KEY WORDS: 3D scanner, Shape analysis, Facial morphology, Soft tissue shifts

ABSTRACT:

To obtain the best surgical results in orthognathic surgery, treatment planning and the evaluation of results should be performed. In these operations it is necessary to provide to the physicians powerful tools able to underline the behaviour of soft tissue. For this reason, considering the improvements provided by the use of 3D scanners, as photogrammetry, in the medical diagnosis this paper proposes a methodology for analysing the facial morphology working with geometrical features. The methodology has been tested over patients affected by malocclusion, in order to analyse the reliability and efficiency of the provided diagnostic results.

1. INTRODUCTION

The assessment of the dimensions and arrangement of facial soft tissues is important for medical evaluations. Orthodontists and orthognathic maxillofacial and plastic surgeons often require quantitative data about the association between soft and hard tissues (Ferrario 1999, Sforza 2005). For many years, this information has been obtained from two-dimensional (2D) radiographs and photos, even if these have been consistently limited (Chew 2005, Koh 2004). Significant improvements have been obtained with the use of computer vision algorithms, even if the use of 2D supports to analyze 3D objects seems to be quite inadequate. For this reason, many research efforts over the last 10 years have been directed toward developing computer vision tools that with the use of 3D scanner devices are able to provide reliable and more complete data. These systems use different technologies such as active or passive light reflection analysis and are able to describe 3D real shapes with a point cloud, analyzable with 3D software. However, while image-processing methodologies are well known in the medical context, the situation for 3D scanners is still quite marginal and fragmented. Some studies have proposed structured procedures that could be used for guiding physicians in the use of 3D scanners in medical diagnosis (Hoffman 2005, Katsumata 2005), but at present no one has succeeded in developing a standardized and accepted strategy.

Actually, it is possible to move from morphometric tools that implement statistical shape analysis, such as Generalised Procrustes Superimposition (GPS) and Principal Component Analysis (PCA). The first iterative method (GPS) applies geometrical transformations (scales, translations, rotations, and reflections) in order to compare reference points (landmarks) (Mori 2005, Sforza 2004) taken from different point clouds of the patient’s face. The PCA method evaluates the tendency of the landmark distributions along the x and y axes, locating a new working frame centered on the average shape center. The method creates new variables named principal components (PCs) that describe how much the landmark configuration of each sample is different from the average shape.

Moving to the 2D radiographs, Thin-Plate Spline analysis (TPS) is used on a point set of anatomical landmarks over the pre- and post-surgery radiograph. Then the postsurgery radiograph is considered as an infinitely thin metal plate that must be bent in a direction orthogonal to the plane in order to match its landmarks to those of the presurgery radiograph while the bending energy is minimized (Hajeer 2004). If the two shapes are identical, the bending energy is zero and the plate is flat.

To provide information regarding face morphology in the regions around the landmarks, the Multisectional Spline method uses section planes passing through a set of specific reference points of a point cloud (landmarks) in order to obtain specific section spline. The shifts of the facial morphology between the pre- and post-surgery point clouds can be analyzed by comparing the two section profiles passing through homologous landmarks and section planes (Soncul 2004).

Working with the entire point cloud instead of only some portions, with the Clearance Vector Mapping method (CVM) the pre- and post-surgery point clouds are first aligned (iterated closest point (ICP), CSM) (McIntyre 2003) and then the magnitude of the 3D shape displacement can be computed by working on triangulated meshes, following different approaches (radial, normal) (Harmon 1981). The displacement is shown by color mapping.

At present, even if the most used methodology for maxillofacial diagnosis remains the Conventional Cephalometric Analysis (CCA) (Bookstein 1991), the Multisectional Splines method seems to be the most reliable and complete methodology because it is able to provide reliable information about the tissue shifts, as does the CCA approach, but it is also able to provide additional global information, e.g., some pathologies such as lateral asymmetry.

Some significant points need work for development of a diagnostic procedure that could be accepted by the entire medical context. It is necessary to define a method that extracts shape morphology measures, starting from the landmarks as reference points, to guarantee consistent morphological comparison, but that also takes into consideration the entire facial shape (point cloud) in order to consider all useful

* E. Vezzetti, Dipartimento di Sistemi di Produzione ed Economia dell’Azienda, Politecnico di Torino, Corso Duca degli Abruzzi 24, 10129 Torino, Italy, email: enrico.vezzetti@polito.it

information. For this reason some studies (Swiderski 1993) have tried to exploit the 3D information from non invasive 3D scanners, such as laser scanners, to extract area and volume measurements. One of the most significant studies (Richtsmeier 1992) has worked on soft tissue landmarks, creating a geometrical model that approximates the facial features with flat

triangles in which vertexes have been represented by the facial landmarks. This approach has provided a simple and direct methodology for supporting the evaluation of facial areas and volumes. However, while the morphological behaviour of the face is characterized by smooth surfaces, this methodology of working with flat triangles is able to provide only a first approximation of the face behavior and neglects a series of features. Considering that 3D scanners provide accurate point clouds, it would be more useful to use methodologies that can exploit the entire point cloud morphology.

Therefore, starting with this concept, we propose a methodology that employs geometrical features for approximating the facial shape, but instead of using only a tetrahedron for describing the face morphology, this methodology employs different 3D geometries that can better fit the face morphology.

2. THE PROPOSED METHODOLOGY: GEOMETRICAL FEATURES BASED APPROACH

To identify the geometries required to develop a geometrical features-based model, it was necessary to define how to decompose the facial morphology. Starting from the head-modelling guidelines (Coombes 1991) and from the coordinates of the facial soft tissue landmarks (Table 1), the face has been divided into four different regions (Fig.1), sectioning the model with a series of planes passing through the vertex, the upper and lower part of the nose, and the chin.

Name	Abbreviation
Nasion	N
Pronalase	Prn
Subnasale	Sn
Labiale superius	Ls
Stomion	Sto
Labiale inferius	Li
Sublabiale	Sls
Pogonion	Pog
Tragion	$t_{right} - t_{left}$
Nasal alar crest	$al_{right} - al_{left}$
Chelion	$ch_{right} - ch_{left}$
Gonion	$go_{right} - go_{left}$
Vertex	V

Table 1. List of soft tissue morphological reference points

Once the four regions are defined, it is necessary to determine which geometry would be the most suitable fit for the different possible shapes in each zone. Starting with the number of landmarks that characterize every identified region, the available 3D geometries, and all the different possible facial morphologies, and working with hypothesis developed from the correlations between the cranial shapes and polygons (Raby 1997), it has been possible to identify the best fitting geometries (Hyun 1998):

Zone 1 (upper face portion): This region could be described by an ellipsoid (Fig.2).

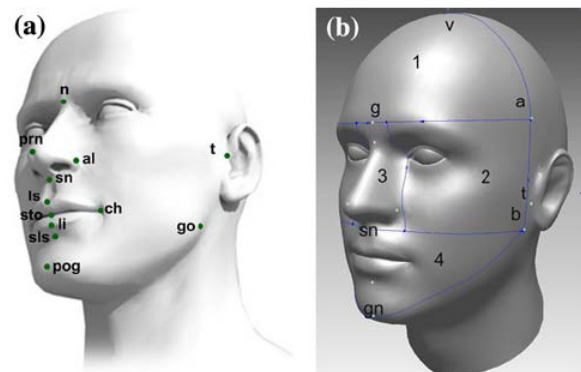


Figure 1. Soft tissue landmarks and face decomposition

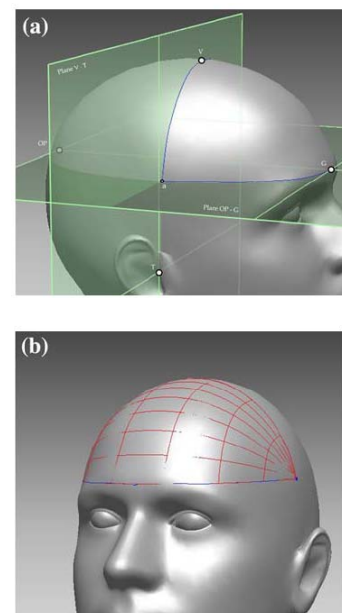


Figure 2. Upper face portion geometrical feature: a) landmarks, b) ellipsoid

Zone 2 (middle face portion): This region could be described by a cylinder with an elliptical shape (Fig.3).

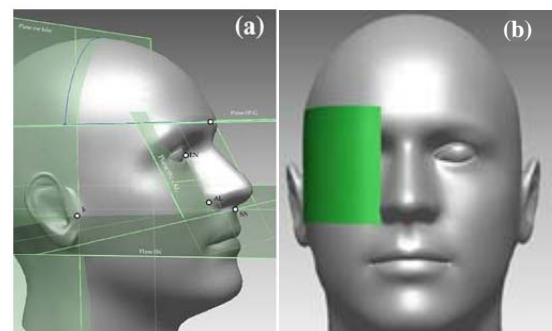


Figure 3. middle face portion geometrical feature: a) landmarks, b) cylinder

Zone 3 (nose): The nose could be described by a conical frustum with an elliptical base (Fig.4).

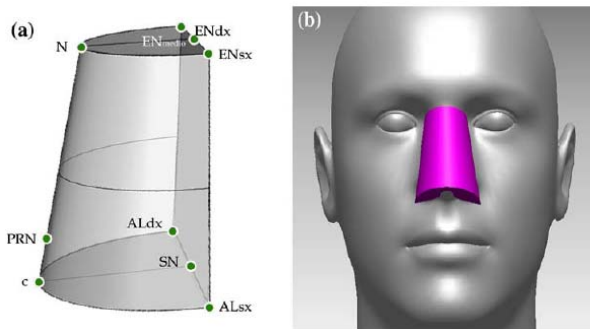


Figure 4. Lower-face portion geometrical feature: a) landmarks, b) conical frustum

Zone 4 (lower-face portion): This region could be described by an ellipsoid (Fig.5).

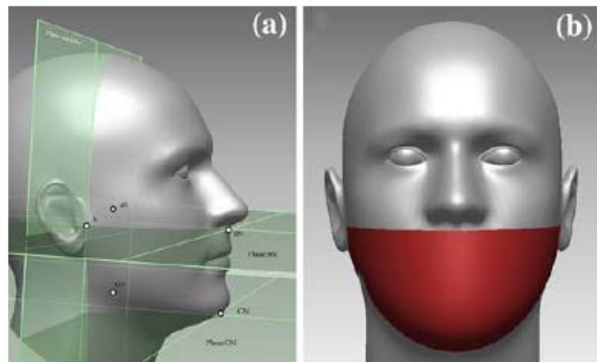


Figure 5. Lower-face portion geometrical feature: a) landmarks, b) ellipsoid

3. EXPERIMENTAL VALIDATION

To evaluate the performance of the proposed methodology in the area evaluation, the geometrical features-based approach was compared with the tetrahedron method (Sforza 2005). First the facial areas of five patients were estimated using the point cloud meshes and adding the area of every single triangle covering the different specific regions. The results from this evaluation were considered reference values because the mesh approximation is very precise and depends only on the 3D scanner device employed for data acquisition. However, using the mesh approximation, it is possible to obtain reliable information about the soft tissue area modifications, but it is impossible to understand, comparing pre and post-surgery point clouds, where the face was modified (shift, scaling, rotation). With the use of specific geometries, such as those used in the proposed method, it is possible to extract spatial information together with reliable data about area and volume. From the results of the different comparisons, the geometrical features-based approach yields data closer to reality than the tetrahedrons methodology.

Looking at the graphical comparison (Fig. 6), it is possible to see that for the nose, while the geometrical features-based approach gives a good fit, the tetrahedron approach does not match the real nose shape. This is verified by the fact that the tetrahedral structure is composed of five vertices: nasion, nose

tip, left and right nose lobes, and nose base. For example, looking at the nose top, while the real shape shows one unique arc profile connecting the eyebrows, the tetrahedron solution employs only one point.

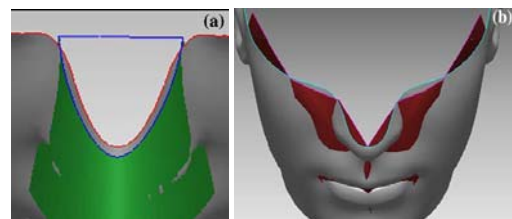


Figure 6. Feature Based Method applied to the nose: a) Feature Based Method, b) Tetrahedron method

This morphological mismatching between the real nose shape and the tetrahedron shape confirms the experimental data that show a more reliable area evaluation using with the conical frustum instead of the tetrahedron.

4. CONCLUSIONS

Face decomposition using solid geometries provides reliable information about the soft tissue shift comparable to that from traditional cephalometric data, but it also provides a more complete set of three-dimensional information, such as facial area modification, that is not attainable with traditional methodology. The presence of elementary geometries that synthesize the real shape is able to support the use of 3D scanners for diagnostic purposes instead of point clouds that contain a huge quantity of morphological data but are very difficult to employ and that sometimes, using inappropriate measurements solutions, provide false information.

Although the method proposed is to study the quantification of postoperative changes, it could also be a starting point for other applications in medical diagnosis thanks to the ability to synthesize facial morphometric data using simple geometrical elements, which is more reliable than the simple tetrahedron.

5. REFERENCES

- Bookstein FL (1991) *Morphometrics tools for landmark data*. Cambridge University Press, Cambridge
- Coombes AM, Moss JP, Linney AD, Richards R, James DR (1991) A mathematical method for comparison of three dimensional changes in the facial surface. *Eur J Orthod* 13:95–110
- Ferrario VF, Sforza C, Schmitz JH, Santoro F (1999) Threedimensional facial morphometric assessment of soft-tissue changes after orthognathic surgery. *Oral Surg Oral Med Oral Pathol Oral Radiol Endod* 88(5):549–556
- Hajeer MY, Ayoub AF, Millett DT (2004) Three-dimensional assessment of facial soft-tissue asymmetry before and after orthognathic surgery. *Br J Oral Maxillofac Surg* 42:396–404
- Harmon LD, Khan MK, Lashc R, Ramig PF (1981) Machine identification of human faces. *Pattern Recognit* 13(2):97–110
- Hoffmann J, Westendorff C, Leitner C, Bartz D, Reinert S (2005) Validation of 3D-laser surface registration for image-guided craniomaxillofacial surgery. *J Craniomaxillofac Surg* 33(1):13–18

Hyun CD, Dong YI, Uk LS (1998) Registration of multiple-range views using the reverse-calibration technique. *Pattern Recogn* 31(4):457–464

Katsumata A, Fujishita M, Maeda M, Ariji Y, Ariji E, Langlais RP (2005) 3D-CT evaluation of facial asymmetry. *Oral Surg Oral Med Oral Pathol Oral Radiol Endod* 99(2):212–220

Koh CH, Chew MT (2004) Predictability of soft tissue profile changes following bimaxillary surgery in skeletal class III Chinese patients. *J Oral Maxillofac Surg* 62:1505–1509

Manual XLSTAT. Available at <http://www.xlstat.com/en/support/tutorials/gpa.htm> [accessed April 21, 2008]

McIntyre GT, Mossey PA (2003) Size and shape measurement in contemporary cephalometrics. *Eur J Orthod* 25:231–242

Mori A, Nakajima T, Kaneko T, Sakuma H, Aoki Y (2005) Analysis of 109 Japanese children's lip and nose shapes using 3-dimensional digitizer. *Br J Plast Surg* 58(3):318–329

Richtsmeier JT, Cheverud JM, Lele S (1992) Advances in anthropological morphometrics. *Ann Rev Anthropol* 21:283–305

Raby GP (1977) Current principles of morphoanalysis and their implementations in oral surgical practice. *Br J Oral Surg* 15:97–109

Sforza C, Dellavia C, Tartaglia GM, Ferrario VF (2005) Morphometry of the ear in Down's syndrome subjects. A three-dimensional computerized assessment. *Int J Oral Maxillofac Surg* 34:480–486

Chew MT (2005) Soft and hard tissue changes after bimaxillary surgery in Chinese class III patients. *Angle Orthod* 75:959–963

Sforza C, Dellavia C, Colombo A, Serrao G, Ferrario VF (2004) Nasal dimensions in normal subjects. Conventional anthropometry versus computerized anthropometry. *Am J Med Genet* 130A:228–233

Soncul M, Bamber MA (2004) Evaluation of facial soft tissue changes with optical surface scan after surgical correction of Class III deformities. *J Oral Maxillofac Surg* 62(11):1331–1340

Swiderski DL (1993) Morphological evolution of the scapula in three squirrels, chipmunks, and ground squirrels (Sciuridae): an analysis using thin-plate splines. *Evolution* 47:1854–1873